

# Dysfunctions of the epididymis as a result of primary carnitine deficiency in juvenile visceral steatosis mice

Kiyotaka Toshimori<sup>a,\*</sup>, Masamichi Kuwajima<sup>b</sup>, Kazuya Yoshinaga<sup>a</sup>, Tomohiko Wakayama<sup>a</sup>, Kenji Shima<sup>b</sup>

<sup>a</sup>Department of Anatomy and Reproductive Cell Biology, Miyazaki Medical College, Miyazaki, Japan

<sup>b</sup>Department of Laboratory Medicine, School of Medicine, The University of Tokushima, Tokushima, Japan

Received 26 January 1999; received in revised form 10 February 1999; accepted 10 February 1999

**Abstract** The juvenile visceral steatosis mutant mice serve as an animal model of primary carnitine deficiency, classified as the sudden infant death syndrome. The defect in carnitine uptake was recently found to be due to a defect in the carnitine transporter gene. We herein report, for the first time, the characteristics of epididymal dysfunction in juvenile visceral steatosis mice. At 8–9 weeks of age, the epididymis was deformed and weight was significantly increased. Histologically, the duct of the proximal epididymis was dilated due to the accumulation of an unusually high level of spermatozoa. Spermatozoa were extravasated from the epididymal duct into the stroma. In contrast, the duct of the distal epididymis was constricted and contained no spermatozoa. Thus, the epididymal disorder causes obstructive azoospermia, leading to infertility.

© 1999 Federation of European Biochemical Societies.

**Key words:** Carnitine deficiency; Epididymis; Azoospermia; Infertility; Juvenile visceral steatosis; Mouse

## 1. Introduction

Mammalian spermatozoa are required to traverse a long duct, the epididymis, in order to become functionally mature [1]. During this process, a variety of epididymal products such as glycoproteins, lipids and inorganic compounds contribute to the maturation [2,3]. Among these, carnitine, which is an essential cofactor in the transport of long chain fatty acid inside the mitochondria and their subsequent beta-oxidation (producing acetyl-CoA), is known to play important roles in the sperm maturation and metabolism when spermatozoa pass and acquire motility in the distal epididymis [4–6]. In fact, in the case of rats, the concentration of free carnitine in the epididymal duct fluid dramatically increases to levels up to 60 mM or 2000 times the concentration in blood which is the highest in the body [5,7]. This occurs in the distal part of the epididymis and spermatozoa actively absorb the carnitine, which is stored as acetylcarnitine and used as a source of energy [4–11].

Therefore, seminal carnitine levels are regarded as an index of androgenization and is also used for determination of the site of obstruction in azoospermia patients [12,13]. Despite such values, however, no animal models for investigating the dysfunctions of the epididymis due to carnitine deficiency

are available, except for several chemical studies which have examined the reduction of carnitine with pivalic acid [5,14].

It is interesting to note that the juvenile visceral steatosis (JVS) mice, discovered by Koizumi et al. [15], represent an animal model for primary carnitine deficiency [16–18] and show their symptoms, which include hyperammonemia, hypoglycemia, cardiomyopathy, fatty liver and weakness [19–21]. The defect was recently found to be due to a missense mutation of the gene encoding octn2, which is identical to human OCTN2 and rat UST2 proteins [22–24]. Since the discovery of human primary carnitine deficiency in 1973 [25], a number of human cases have been reported [26] and recently some cases have been shown to be due to a defect in the OCTN2 gene [27,28].

In this study, we report, for the first time, epididymal disorders induced in a primary carnitine deficiency animal model, namely the JVS mouse.

## 2. Materials and methods

### 2.1. Animals

The JVS mice used in this study were B6/JVS, which were obtained by back-crossing the autosomal recessive mutant gene from C3H/JVS mice [29,30]. C57BL/6J mice were assigned as controls. Animals were maintained under pathogen-free conditions. All procedures were performed according to the guideline for the care and use of laboratory animals, were monitored by the institutional animal care and use of the University of Tokushima and the Miyazaki medical college.

Since primary carnitine deficiency is infantile onset, progressive and lethal, most of the JVS mice died within 5 weeks after birth unless they received therapeutic intervention, involving the intraperitoneal injection of L-carnitine. Typically, the neonatal JVS mice were given an intraperitoneal injection of L-carnitine (1  $\mu$ mol/g body weight) each morning from 10 to 20–25 days after birth. The surviving male mice and control male mice were killed at 8–9 weeks after birth for this study.

### 2.2. Weight of body and epididymis

The body weights were determined prior to the experiments, while the wet weight of the epididymis was determined immediately after perfusion fixation described below. The epididymis weight/body weight ratio (EW/BW) was then calculated and statistically analyzed for both the JVS mice and the control mice.

### 2.3. Morphological study

After anesthesia with ether, the animals were perfused with 4% paraformaldehyde in phosphate buffer for paraffin sections. Epididymides were removed and separated individually for weighing and were then processed for histological analysis.

### 2.4. Statistical analysis

Results are expressed as mean  $\pm$  S.D. and the data were analyzed by using the Student's *t*-test. Probability values of less than 5% were considered significant.

\*Corresponding author. Fax: (81) (985) 85 1363.  
E-mail: ktoshi@post.miyazaki-med.ac.jp

Table 1  
Comparison of the epididymis weight between JVS (juvenile visceral steatosis) mice and C57BL/6J (control) mice

| Animal             | Epididymis           |                                  |
|--------------------|----------------------|----------------------------------|
|                    | Total number weighed | Weight ratio*(% mean $\pm$ S.D.) |
| JVS                | 8                    | 0.16 $\pm$ 0.03 <sup>a</sup>     |
| C57BL/6J (control) | 7                    | 0.14 $\pm$ 0.02 <sup>a</sup>     |

\*(EW/BW)  $\times$  100.

$P < 0.05$ : <sup>a</sup>.

### 3. Results

#### 3.1. Epididymis weight

In JVS mice, the weight ratio of epididymis, EW/BW, was significantly increased ( $P < 0.05$ ) compared to the control mice. The results are summarized in Table 1.

#### 3.2. Outward appearance

The JVS mouse epididymides were deformed in appearance (Fig. 1). The juncture between the caput and the corpus was

strongly flexed in the JVS mice. The proximal portion from the caput to mid-corpus was characteristically swollen, while the distal portion from the distal corpus to the cauda was constricted and somewhat transparent in appearance in the JVS mice.

#### 3.3. Histological findings

In the JVS mice, the duct of the proximal epididymis was dilated due to unusual accumulations of spermatozoa and the epithelial cells were low columnar or cuboidal (Fig. 2A). In the mid-corpus region of most severe cases, the epididymal epithelium was ruptured and spermatozoa were extravasated through the ruptured epithelium into the stroma (Fig. 2B). The duct of the distal epididymis was filled with extremely condensed eosinophilic materials and contained no spermatozoa (Fig. 2C). The epithelial cells were rather columnar. In some cases, only aqueous materials interspersed with eosinophilic debris were observed. These findings were found in six out of six mice examined (100%), but the extent of the disorder was somewhat diverse among mice. Complete obstruction with absolutely no sperm was found in four mice (eight epididymides) and incomplete obstruction with only a trace of sperm was found in two mice (four epididymides).

In control mice, the duct of the proximal epididymis contained ordinary amounts of spermatozoa and the epithelial cells were high columnar (Fig. 2D). From the corpus to the distal epididymis, the duct contained considerable amounts of spermatozoa and the epithelial cells changed from low columnar to cuboidal or flattened with increments of sperm accumulation (Fig. 2E and F).

#### 3.4. Fertility

Only a small number (less than 10%) of JVS neonatal mice were able to survive, showing weakness, to 8 weeks, unless they received therapeutic intervention of L-carnitine. Thus, the JVS strain mice were substantially infertile but the infertility was effectively restored after L-carnitine treatment as described in Section 2. The rescued JVS male mice lived to more than 66 weeks as of this writing and serve as breeder males.

### 4. Discussion

Among epididymal dysfunctions due to carnitine deficiency, abnormal passage of spermatozoa in the epididymis leading to obstructive azoospermia is most characteristic. The most susceptible region is the distal epididymis where the passage of spermatozoa was hindered. The obstruction apparently induces the increment of the epididymis weight due to swelling of the proximal epididymis. This macroscopic deformity of the proximal epididymis completely accounts for the submicroscopic abnormality. However, these dysfunctions and infertility

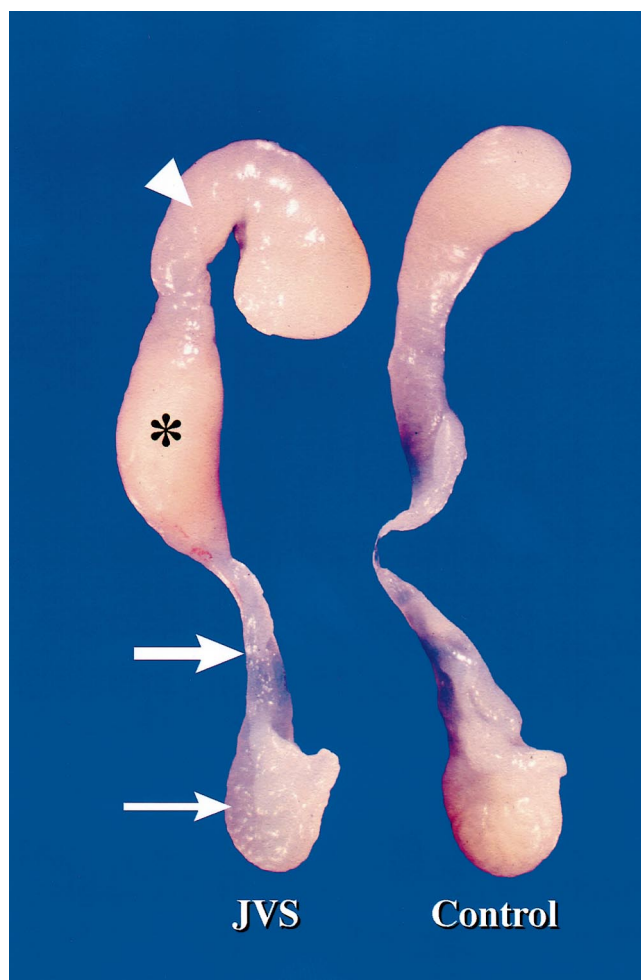


Fig. 1. Stereoscopic photograph showing the outward appearance of the epididymides. Left: JVS. Right: control. Top: proximal. Bottom: distal. Note the strong flexure between the caput and corpus (arrowhead), the swollen region from caput to mid-corpus (asterisk), the obstruction point (large arrow) and the somewhat transparent, constricted cauda (small arrow) in the JVS mice. The epididymis of control mice is normal in appearance.

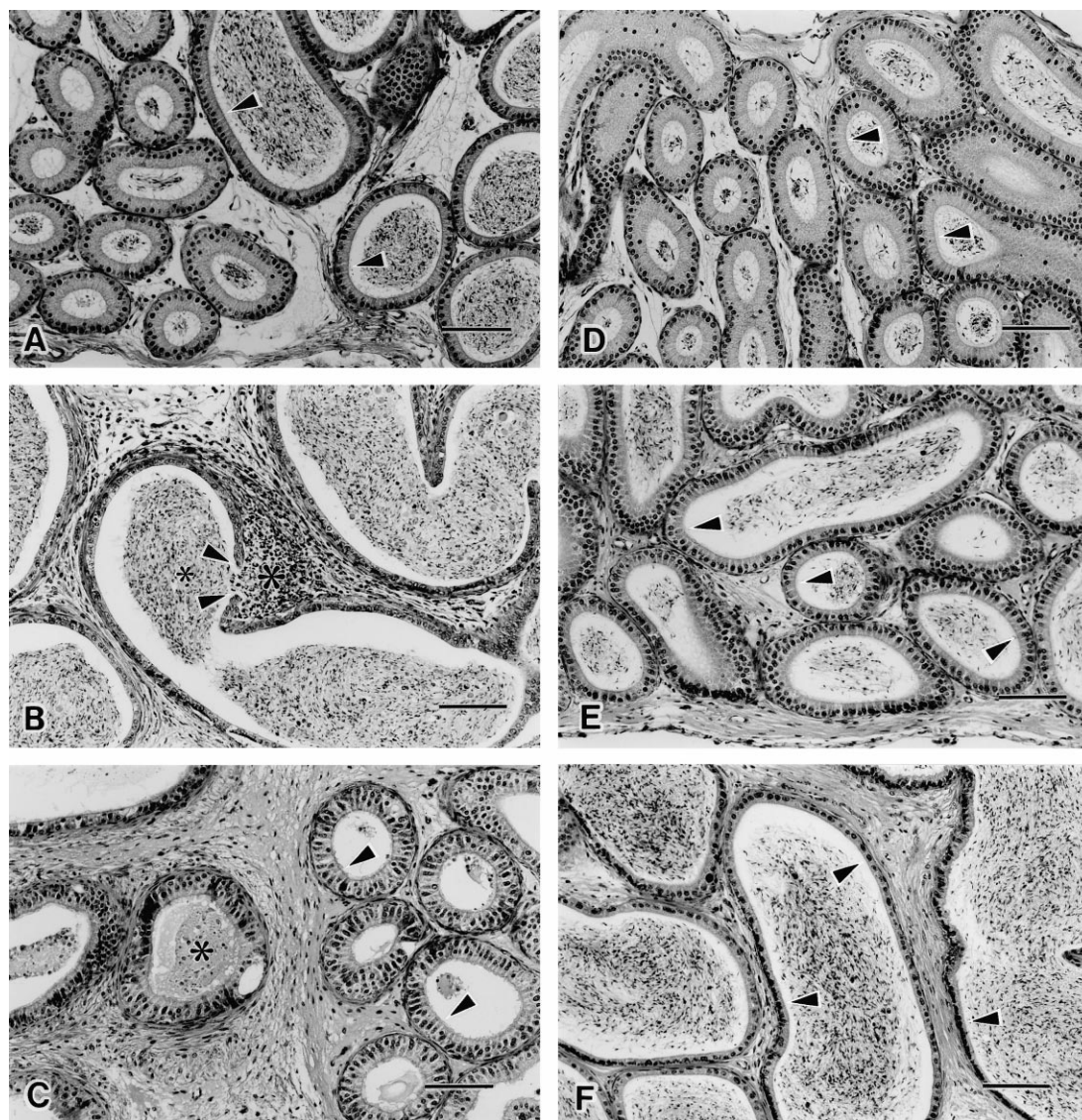


Fig. 2. Light micrographs of the epididymides of the JVS mouse (A–C) and the control mouse (D–F). A and D: Corresponding proximal corpus. B and E: Corresponding mid-corpus. C and F: Corresponding cauda. Haematoxylin-eosin staining. Left: proximal. Right: distal. A: Note the dilated duct due to the unusual accumulation of spermatozoa (compare to D) and epithelial cells with a low columnar shape (arrowheads). B: Note the extravasation of spermatozoa from the duct lumen (small asterisk) into the stroma (large asterisk) through the ruptured, flattened epithelium (between arrowheads). C: Note the duct, which is completely filled with condensed eosinophilic materials (asterisk). The epithelium is rather high columnar in the duct with few material present (arrowheads). D: Normal appearance with typically accumulated spermatozoa and high columnar epithelium (arrowheads). E and F: Typical presence of large amounts of spermatozoa and low columnar (E) and flattened (F) epithelium (arrowheads). Scale bar = 120 μm.

can be effectively restored by L-carnitine therapeutic intervention.

These observations are of clinical interest, since the genetic defect associated with carnitine uptake was recently discovered in human patients. The defect has been attributed to the genes which encode the sodium ion-dependent carnitine transporter, OCTN2 [27,28]. Interestingly, the mouse *octn2* is highly homologous to the human OCTN2 [23,24] as well as the rat UST2 [22]. Hence, the JVS mouse warrants further investigations of the molecular mechanism involved in the disorder as well as normal lipid metabolism of the epididymis.

Regarding impaired sperm passage, although the precise mechanism is unclear, several possible explanations exist for this. Spermatozoa and epididymal epithelial cells actively ab-

sorb free carnitine which is stored as acetylcarnitine in the distal epididymis [7–11]. Maturing spermatozoa also require a carnitine-dependent energy source in order to traverse and survive in the distal epididymis [4–6]. Therefore, due to a carnitine deficiency, the JVS mouse spermatozoa presumably cannot pass and survive in the distal epididymis, which leads to the observed obstruction. We also cannot ignore another possibility that stromal components such as fibroblasts and smooth muscle cells may also participate, at least partly, in the obstruction. The reason for this is that they absorb carnitine [5] but lack carnitine transport in the case of JVS mice [18]. Presumably this makes such epididymal sustentacular tissues too frail to support the transport of large amounts of spermatozoa. Eventually, this, together with epithelial dys-

functions, causes extravasation of spermatozoa into the stro-ma. This would be expected to induce the migration of im-munoreactive cells, thus eliciting anti-sperm antibodies.

Regarding the testis of the JVS mice, its weight ratio was significantly reduced with ordinary appearance (oval in shape) and spermiogenesis was sporadically arrested in some semi-niferous tubules, although spermiogenesis occurred in a typi-cal manner in most tubules (unpublished data). Based on the data now available, it is plausible to assume that such a spor-adic spermiogenesis arrest is a sign of progressive, self-perpet-uating spermatogenesis arrest. However, we cannot absolutely verify this point at present, because of the difficulty in obtain-ing a sufficient number of suitable material since only small numbers of JVS infant mice survive up to 8 weeks. This issue is under investigation in our laboratory. Also due to paucity of materials, we could not determine the carnitine content in sperm and each segment of the epididymis in this study and this issue remains to be solved in the next project. If this issue is solved, then the relationship between the carnitine content and the sperm motility will be clarified.

No prominent abnormality in terms of outward appearance was found in other male genital organs such as the prostate, seminal vesicles and coagulating glands.

In summary, carnitine deficiency in the JVS mutant mouse, which is an animal model of primary carnitine deficiency due to a defect of the carnitine transporter gene, *octn2*, causes obstructive dysfunctions of the epididymis, leading to infertili-ty.

**Acknowledgements:** The authors are grateful to Mr Y. Fujii for his excellent technical assistance and to Miss H. Kiyotake for word pro-cessing. This study was supported by grants from the Ministry of Education, Science, Sports and Culture of Japan to K.T. and to M.K..

## References

- [1] Toshimori, K. (1998) *Cell Tissue Res.* 293, 177–187.
- [2] Robair, B. and Hermo, L. (1988) in: *The Physiology of Repro-duction* (Knobil, E. and Neill, J.D., Eds.), 1st edn, Vol. 1, pp. 999–1080, Raven Press, New York.
- [3] Setchel, B.P., Maddocks, S. and Brooks, D.E. (1994) in: *The Physiology of Reproduction* (Knobil, E. and Neill, J.D., Eds.), 2nd edn, Vol. 1, pp. 1063–1175, Raven Press, New York.
- [4] Brooks, D.E. (1980) in: *Carnitine Biosynthesis, Metabolism and Functions* (Frenkel, R.A. and McGarry J.D., Eds.), pp. 219–235, Academic Press, New York.
- [5] Bremer, J. (1983) *Physiol. Rev.* 63, 1420–1480.
- [6] Jeulin, C. and Lewin, L.M. (1996) *Hum. Reprod. Update* 2, 87–102.
- [7] Hinton, B.T., Snoswell, A.M. and Setchell, B.P. (1979) *J. Re-prod. Fertil.* 56, 105–111.
- [8] Jones, R. (1978) *Comp. Biochem. Physiol.* 61, 365–370.
- [9] Casillas, E.R., Villalobos, P. and Gonzales, R. (1984) *J. Reprod. Fertil.* 72, 197–201.
- [10] Soufir, J.C., Marson, J., Paquignon, M. and Dacheux, J.L. (1988) *Reprod. Nutr. Dev.* 28, 1317–1327.
- [11] Fourie, M.H., du Toit, D., Bornman, M.S. and Viljoen, E. (1995) *Andrologia* 27, 239–243.
- [12] Abbaticchio, G., Giagulli, V.A., Defini, M., Micale, F.M. and Giorgino, R. (1985) *Arch. Androl.* 15, 137–142.
- [13] Moncada, M.L., Vicari, E., Cimino, C., Calogero, A.E., Mon-gioi, A. and D'Agata, R. (1992) *Acta Eur. Fertil.* 23, 221.
- [14] Cooper, T.G., Wang, X.S., Yeung, C.H. and Lewin, L.M. (1997) *Int. J. Androl.* 20, 80–88.
- [15] Koizumi, T., Nikaido, H., Hayakawa, J., Nonomura, A. and Yoneda, T. (1988) *Lab. Anim.* 22, 83–87.
- [16] Kuwajima, M., Kono, N., Horiuchi, M., Imamura, Y., Ono, A., Inui, Y., Kawata, S., Koizumi, T., Hayakawa, J., Saheki, T. and Tarui, S. (1991) *Biochem. Biophys. Res. Commun.* 174, 1090–1094.
- [17] Horiuchi, M., Kobayashi, K., Yamaguchi, S., Shimizu, N., Koizumi, T., Nikaido, H., Hayakawa, J., Kuwajima, M. and Saheki, T. (1994) *Biochim. Biophys. Acta.* 1226, 25–30.
- [18] Kuwajima, M., Lu, K., Harashima, H., Ono, A., Sato, I., Miz-uno, A., Murakami, T., Nakajima, H., Miyagawa, J., Namba, M., Hanafusa, T., Hayakawa, J., Matsuzawa, Y. and Shima, K. (1996) *Biochem. Biophys. Res. Commun.* 223, 283–287.
- [19] Horiuchi, M., Kobayashi, K., Tomomura, M., Kuwajima, M., Imamura, Y., Koizumi, T., Nikaido, H., Hayakawa, J. and Sa-heki, T. (1992) *J. Biol. Chem.* 267, 5032–5035.
- [20] Kuwajima, M., Lu, K., Sei, M., Ono, A., Hayashi, M., Ishiguro, K., Ozaki, K., Hotta, K., Okita, K., Murakami, T., Miyagawa, J.-I., Aarama, I., Nikaido, H., Hayakawa, J.-I., Nakajima, H., Namba, M., Hanafusa, T., Matsuzawa, Y. and Shima, K. (1998) *J. Mol. Cell Cardiol.* 30, 773–781.
- [21] Kuwajima, M., Horiuchi, M., Harashima, H., Lu, K.-M., Hay-ashi, M., Sei, M., Ozaki, K., Kudo, T., Kamido, H., Ono, A., Saheki, T. and Shima, K. (1999) *FEBS Lett.* (in press).
- [22] Schomig, E., Spitzenberger, F., Engelhardt, M., Martel, F., Ord-ing, N. and Grundemann, D. (1998) *FEBS Lett.* 425, 79–86.
- [23] Tamai, I., Ohashi, R., Nezu, J., Yabuuchi, H., Oku, A., Shimane, M., Sai, Y. and Tsuji, A. (1998) *J. Biol. Chem.* 273, 20378–20382.
- [24] Lu, K.-M., Nishimori, H., Nakamura, Y., Shima, K. and Kuwa-jima, M. (1998) *Biochem. Biophys. Res. Commun.* 252, 590–594.
- [25] Engel, A.G. and Angelini, C. (1973) *Science.* 179, 899–902.
- [26] Treem, W.R., Stanley, G.A., Finegold, D.N., Hale, D.E. and Coates, P.M. (1998) *New Engl. J. Med.* 319, 1331–1336.
- [27] Lamhonwah, A.M. and Tein, I. (1998) *Biochem. Biophys. Res. Commun.* 252, 396–401.
- [28] Nezu, J.-I., Tamai, I., Oku, A., Ohashi, R., Yabuuchi, H., Ha-shimoto, N., Nikaido, H., Sai, Y., Koizumi, A., Shoji, Y., Taka-da, G., Matsuishi, T., Yoshino, K., Kato, H., Ohura, T., Tsuji-moto, G., Hayakawa, J.-I., Shimane, M. and Tsuji, A. (1999) *Nat. Genet.* 21, 91–94.
- [29] Hayakawa, J., Koizumi, T. and Nikaido, H. (1990) *Mouse Ge-nome* 86, 261.
- [30] Okita, K., Tokino, T., Nishimori, H., Miura, K., Nikaido, H., Hayakawa, J., Ono, A., Kuwajima, M., Matsuzawa, Y. and Na-kamura, Y. (1996) *Genomics* 33, 289–291.